

# Moderate Controlled Cortical Contusion in Pigs: Effects on Multi-Parametric Neuromonitoring and Clinical Relevance

BEAT ALESSANDRI,<sup>1</sup> AXEL HEIMANN,<sup>1</sup> RONALD FILIPPI,<sup>2</sup> LASZLO KOPACZ,<sup>1</sup>  
and OLIVER KEMPSKI<sup>1</sup>

## ABSTRACT

Over the last decade, routine neuromonitoring of ICP and CPP has been extended with new on-line techniques such as microdialysis, tissue oxygen (ptiO<sub>2</sub>), acid-base balance (ptiCO<sub>2</sub>, pH) and CBF measurements, which so far have not lead to clear-cut therapy approaches in the neurointensive care unit. This is partially due to the complex pathophysiology following a wide-range of brain injuries, and the lack of suitable animal models allowing simultaneous, clinically relevant neuromonitoring under controlled conditions. Therefore, a controlled cortical impact (CCI) model in large animals (pig) has been developed. After placement of microdialysis, ptiO<sub>2</sub>, temperature and ICP catheters, an unilateral CCI injury (2.6–2.8 m/sec velocity, 9 mm depth, 400 ms dwell time) was applied and neuromonitoring continued for 10 h. CCI caused a rapid drop in CPP, ptiO<sub>2</sub> and glucose, whereas ICP, glutamate and lactate increased significantly. Most parameters returned to baseline values within hours. Lactate stayed elevated significantly throughout the experiment, but the lactate-to-pyruvate ratio (LPR) changed only slightly, indicating no severely ischemic CBF. Contralateral parameters were not affected significantly. Evaluation of brain water content and histology (12 h post-CCI) showed ipsilateral brain swelling by 5% and massive cell damage underneath the injury site which correlated with changes of ICP, CPP, glutamate, lactate, and ptiO<sub>2</sub> within the first hours post-CCI. Moderate controlled cortical contusion in pigs induced a complex pattern of pathophysiological processes which led to ‘early’ histological damage. Thus, this new large animal model will enable us to investigate the effect of therapeutic interventions on multi-parametric neuromonitoring and histological outcome, and to translate the data into clinical practice.

**Key words:** controlled cortical impact; microdialysis; monitoring; pig; ptiO<sub>2</sub>

## INTRODUCTION

**T**RAUMATIC BRAIN INJURY (TBI) is associated with pathophysiological changes all leading to biochemical, molecular and structural changes within the brain and finally to cell death. Research efforts aim to prevent or

reduce the pathophysiological cascade in order to provide neuroprotection to the traumatized brain tissue. Although successful in animal models of TBI [e.g. (Alessandri and Bullock, 1998)], pharmacological strategies have not translated into neuroprotective clinical therapies (Narayan et al., 2002).

---

<sup>1</sup>Institute for Neurosurgical Pathophysiology and <sup>2</sup>Department of Neurosurgery, Johannes Gutenberg–University Mainz, Mainz, Germany.

Therefore, the pre-clinical and clinical approach of the last decade has been to monitor brain metabolism, biochemistry, and function more closely and simultaneously, in order to find correlates for outcome or time-points for therapeutical interventions following TBI. Simultaneous monitoring of ICP, interstitial fluid constituents by microdialysis, brain tissue oxygen ( $p_{ti}O_2$ ), acid-base balance ( $p_{ti}CO_2$ , pH), temperature, as well as local CBF are frequently added to routine monitoring of trauma patients (Alessandri et al., 1999; Bullock et al., 1995; Bullock et al., 1995; Dings et al., 1996; Goodman et al., 1996; Goodman et al., 1999a; Goodman et al., 1999b; Hillered et al., 1990; Landolt et al., 1994; Reinert et al., 2000; Stocchetti et al., 2001; Unterberg et al., 2001; Vajkoczy et al., 2000; Valadka et al., 1998; Van Den Brink et al., 2000; Van Santbrink et al., 1996; Vath et al., 2000; Zauner et al., 1997a; Zauner et al., 1997b). The selection of parameters for such a simultaneous multi-parametric neuromonitoring is based on a chain of pathophysiological events which includes excitotoxic glutamate release (Alessandri and Bullock, 1998; Palmer et al., 1993), massive ionic shifts imposing high energy demand and hyperglycolysis on cells (Alessandri et al., 1996; Bergsneider et al., 1997; Katayama et al., 1990), cytotoxic edema formation (Kempinski et al., 1990; Kochanek et al., 1995; Kroppenstedt et al., 1999) and local or global ischemic CBF with reduced substrate and oxygen supply to the tissue (Bouma et al., 1992; Bryan et al., 1995). These mechanisms and their detectable correlates in the tissue were investigated one-by-one in small animal models of cortical contusion, but only few attempts were made to study them simultaneously under controlled conditions [e.g., (Clausen et al., 2001; Zauner et al., 1995; Zauner et al., 2002)]. Having a controlled TBI model in large animals would be important, since experimental and clinical data suggest a rather unexpected complex relationship of neuromonitoring parameters. This complexity becomes especially obvious when parameters are measured at the same time and in the same animal/patient and the injury is not maximal. For instance, low oxygen level and/or high lactate-to-pyruvate ratio (LPR) could indicate ischemic conditions in the monitored area. However, high oxygen levels alone do not necessarily indicate viable tissue. If tissue at risk is not metabolizing,  $p_{ti}O_2$  will be elevated to "healthy" levels (Clausen et al., 2001). This could also be the case in severely head-injured patients in which an initial hyperglycolysis turns into hypoglycolysis within hours to days after TBI (Bergsneider et al., 2000; Bergsneider et al., 1997). In addition, Unterberg and coworkers reported that the effect of increasing CPP as therapy on  $p_{ti}O_2$  depends on the type of intervention in patients, i.e. despite a global increase of CPP is achieved with each therapy,  $p_{ti}O_2$  did not respond uni-

formly (Kiening et al., 1997). Furthermore, an enormous variability of (uncontrolled) traumatic brain injuries is seen in patients that also complicates comparison of the effects of injury and therapy on multi-parametric neuromonitoring. Thus, the complexity of tissue reactions and therapy comparable to those seen in patients can be ideally studied in animal models in which a similar brain structure exists (gyri/sulci), clinically relevant multi-parametric neuromonitoring can be applied (brain size), and a controlled injury can be induced. Therefore, we developed a model of controlled cortical impact (CCI) injury in pigs which enables the application of clinically relevant multi-parametric monitoring as used in neurointensive care units. In this report, we describe the effect of a moderate unilateral cortical injury on physiological parameters, ICP, CPP, edema formation, glutamate, lactate, LPR, glucose and brain oxygen tension as well as temperature.

## MATERIALS AND METHODS

### *Animals and Anesthesia*

All experiments were performed under the *Animal Welfare Guidelines* and were approved by the local ethics committee. We used adult male pigs (German breed), weighing 25–30 kg, which were divided into a sham-operated group (SHAM,  $n = 5$ ) and a trauma group (CCI,  $n = 6$ ). They were initially anesthetized by an intramuscular (neck) injection of a mixture of ketamine (15 mg/kg), stesnil (3 mg/kg) and atropine (1 mg; total of 8 mL/30kg in saline). Thereafter, anesthesia was maintained by hourly injections of 20–40 mL alpha-chloralose (5 g [Reactifs Ral, Martillac, France] + 4 g  $Na_2B_4O_7$  [Merck] in 100 mL NaCl, adjusted pH 7.4). Dipidolor (Janssen-Cilag GmbH, Neuss, Germany) was used for analgesia.

### *Surgical Preparation*

Left femoral vein and artery were cannulated using F8-catheters for blood pressure monitoring, blood gas analysis and drug infusion. The head was fixed in a stereotaxic frame and the skull was exposed. A large craniectomy (diameter 30 mm) was drilled carefully over the left parietal cortex. At a distance of 5 mm posterior to the craniotomy (ipsilateral) and at the same positions above the contralateral hemisphere, burr holes were prepared for neuromonitoring catheters (Fig. 1). An additional hole was made contralaterally for an intraventricular ICP-catheter. After probe insertion, burr holes were closed using bone wax, whereas a cover made out of Refobacin®-Palacos® R (Merck Biomaterial, Darmstadt, Germany) or

Alginat<sup>®</sup> Quick (Demedis, Düsseldorf, Germany) was used to close the craniotomy.

### Controlled Cortical Impact

The unilateral CCI injury was induced using a newly designed device for large animals (Fig. 1; modified from Dixon et al., 1991). Briefly, the device consists of a guiding frame with an impactor, electronics and a light sensor, all fixed inside. The device was mounted on a rigid frame and was connected to a pressure tank and an electronic controller which recorded impact velocity at impact (Fig. 1) and controlled dwell time. Before CCI the pneumatically driven stainless-steel tip was carefully placed on the dural surface and cortical injury depth and duration were set to 9 mm and 400 msec, respectively. Impact velocity ranged from 2.6 to 2.8 m/sec. After trauma, the CCI device was removed and the craniotomy closed with the cap which was now fixed to the skull and left in place throughout the experiment. Sham-operated animals received the same treatment, except for the CCI injury.

### Neuromonitoring and Experimental Protocol

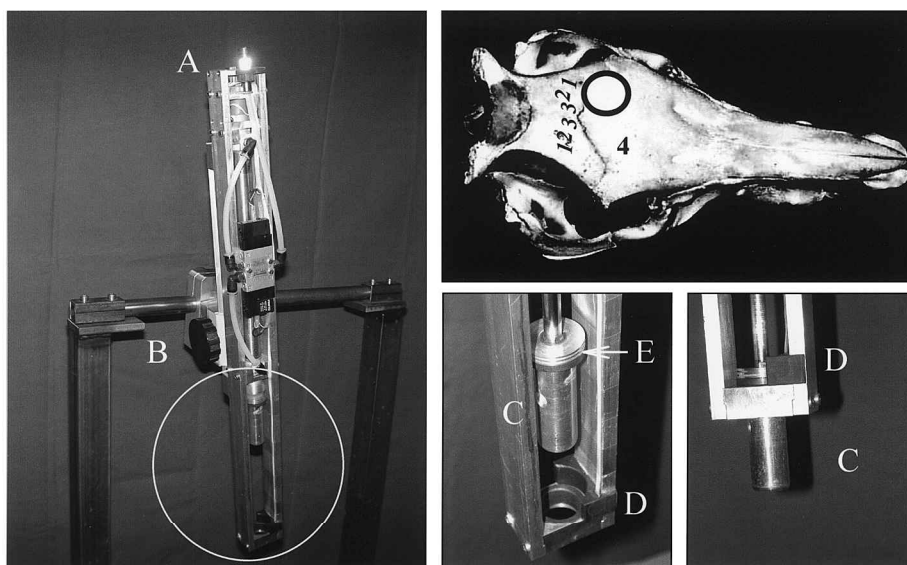
ICP was monitored continuously using a saline-filled PE-tubing (i.d. 0.58 mm) that was connected to a pres-

sure transducer. The ICP catheter was always introduced i.c.v. on the contralateral side.

Two microdialysis catheters (CMA/70, 10 mm membrane length, Axel Semrau GmbH, Germany) were implanted bilaterally after perforating the dura by a 20G needle and lowered to a depth of 15 mm. Immediately after insertion, probes were perfused with artificial CSF at a flow rate of 1  $\mu$ L/min. Dialysate samples were collected into microvials (CMA/Microdialysis). All dialysate samples were immediately frozen at  $-20^{\circ}\text{C}$  and analyzed for glutamate, glucose, lactate and pyruvate using the CMA/600 enzymatic analyzer.

The Licox catheter system (Integra Ltd, UK) was used, combining brain tissue oxygen pressure ( $\text{ptiO}_2$ ) and temperature measurement. As outlined in Figure 1, both sensors were inserted bilaterally next to the microdialysis catheters. Probes were separated by about 3 mm from each other (Fig. 1).

After placement, all catheters were allowed to equilibrate for 1–2 h, and baseline recording was started when  $\text{ptiO}_2$  values were stable. In all experiments, neuromonitoring consisted of a 60-min baseline and a 600-min post-traumatic monitoring period. In all graphs, time of CCI is marked as 0. Data were recorded at least every 15 min throughout the experiment, except for the first 30 min post-CCI, when the collection interval was 1 min (0.5–10



**FIG. 1.** Newly designed controlled cortical impact injury device for large animals. The entire device is fixed on a rigid metal frame and can be moved by screw B, which allows adjusting injury depth precisely. Connections for a high-pressure line and for an electronic controller used to pre-set dwell time, to release the impactor tip (C,  $\text{Ø}$  20 mm), and to record velocity are both located on the top of the device (A). Velocity is measured at impact by means a sensor at the bottom of the device (D). The sensor records the time between the passage of two black marks (E, arrow) on the upper end of the tip which have a defined distance from each other, i.e., the calculation of the exact velocity at impact is possible. Note that, as shown on the inlet, monitoring catheters (1 = microdialysis, 2 =  $\text{p}_i\text{O}_2$ ; 3 = temperature) were placed 5 mm posterior to a large craniectomy and contralaterally. ICP (4) was measured intraventricularly.

min post-CCI) and 5 min (15–30 min post-CCI). For microdialysis, sampling interval was 15 min until 3 h post-CCI. Thereafter hourly samples were collected until the end of the experiment.

### *Brain Water Content and Histology*

At the end of the experiment, all intracranial catheters were carefully removed. The brain was exposed, quickly removed and sliced (without cerebellum) into five coronal blocks.

In three traumatized and five sham-operated animals, one block containing part of the injury site was immediately processed for water content analysis using the wet-to-dry weight method (Kempinski et al., 1990). The two hemispheres were separated and each dorsal half was put into a pre-weighed glass container. After determining wet weight, containers were dried in an oven at 110°C for 24 h and then re-weighed using the same scale. Percent (%) water content and swelling were calculated.

For histological analysis, all other blocks were immersed in paraformaldehyde for several days and embedded in paraffin. Coronal sections (3  $\mu$ m thick) from blocks containing the anterior or posterior brain coordinate of 4.5 and 12.5 mm, respectively (Felix et al., 1999), were cut, stained by hematoxylin-eosin and histologically analyzed and scored. Each gyrus was then scored for hemorrhages (0 = no, 1 = scattered/small, 2 = distinct, 3 = massive with tissue rupture) and changes of cell appearance (swelling, shrinkage, nucleus, plasma, nissl substance) summarized as cell injury (0 = no, 1 = slight, 2 = distinct, 3 = massive). On each section white and gray matter were scanned and scored separately on each gyrus, as defined above. The *injury score* for each animal consisted of the sum of all scores of both analyzed sections. In addition, a published score, contusion index (Adams et al., 1985) was used to verify the early histological damage described by our injury score.

### *Statistical Analysis*

Statistical analysis was performed for four different time periods within the entire time course of 11-h monitoring, namely for a baseline period (–60 to 0 min post-CCI), an acute (0.5 to 60 min post-CCI), intermediate (180 to 300 min post-CCI) and late (480 to 600 min post-CCI) post-trauma period. For all neuromonitoring parameters, comparisons of groups and time points were made using two-way repeated measures ANOVA with Student-Newman-Keuls post-hoc tests. Due to large baseline differences between animals in microdialysis parameters, values were normalized to baseline and expressed as percentage change from baseline. Brain water content and physiological data were analyzed using *t*-tests. Area-

under-curve (AUC) was calculated using Sigmaplot 7.0 for each animal separately and correlated using Spearman rank correlation analysis (SigmaStat 2.0 for all statistics) with injury score. In addition, a neuronal network software (NeuroModel<sup>®</sup>, ATLAN-tec, Willau, Germany), which integrates the complex relationship of neuromonitoring parameters, was used to evaluate the prediction sensitivity of these parameters for histological outcome.

## RESULTS

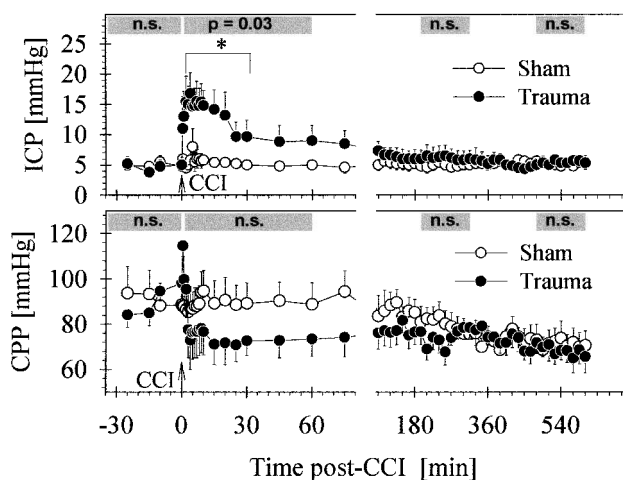
### *Physiological Data*

Physiological parameters were within normal ranges in both groups throughout the entire experiment. In injured animals, pH, pCO<sub>2</sub>, pO<sub>2</sub>, glucose, and lactate at baseline and at 600 min post-TBI (in brackets) were 7.47  $\pm$  0.004 (7.41  $\pm$  0.01), 45.0  $\pm$  1.1 mm Hg (45.7  $\pm$  0.7), 127.3  $\pm$  8.7 mm Hg (138.1  $\pm$  10), 97.8  $\pm$  7.8 mg/dL (80.0  $\pm$  11.9), and 1.1  $\pm$  0.1 mM (1.5  $\pm$  0.5), respectively. Values for the sham group were 7.43  $\pm$  0.01 (7.41  $\pm$  0.04); 48.6  $\pm$  0.6 mm Hg (45.9  $\pm$  2.6); 141.4  $\pm$  7.6 mm Hg (122.2  $\pm$  17.9); 94.7  $\pm$  4.5 mg/dL (78.3  $\pm$  4.7); 0.8  $\pm$  0.1 mM (1.4  $\pm$  0.5). CCI injury caused only marginal changes blood values.

Mean arterial blood pressure (MABP) was 96.7  $\pm$  0.8 mm Hg (Sham) and 93.0  $\pm$  2 mm Hg (Trauma) during baseline. MABP increased significantly at 0.5 min post-CCI (Sham = 91.9  $\pm$  5.1; Trauma = 128.5  $\pm$  4.6 mm Hg), followed by a drop below baseline and sham group levels (Sham: 94.4  $\pm$  4.3; Trauma: 75.3  $\pm$  6.3 at 30-min post-CCI;  $p < 0.05$  at 30, 45, and 60 min). Thereafter MABP was comparable in both groups.

### *Neuromonitoring Data*

*ICP and CPP.* Baseline ICP was 4.80  $\pm$  0.51 mm Hg and 5.06  $\pm$  1.01 mm Hg for the sham and trauma group, respectively. Injury increased ICP to a maximum of 15.50  $\pm$  3.08 mm Hg. Thereafter ICP declined slowly, finally reaching sham group levels at 120 min post-CCI. The intracranial pressure of sham pigs remained stable (Fig. 2, top). Statistics using two-way repeated measures ANOVA revealed no significant difference between the sham-operated and traumatized group for ICP in the baseline period ( $p = 0.834$ ), the intermediate and late post-traumatic periods (180–300 min,  $p = 0.527$ ; 480–600 min,  $p = 0.842$ ). Baseline CPP was 94.8  $\pm$  6.7 (Sham) and 88.9  $\pm$  6.1 mm Hg (Trauma). Perfusion pressure dropped within 25 min to a minimum of 70.8  $\pm$  4.8 mm Hg in the traumatized pigs following CCI. Statistical analysis of CPP showed no significant differences between the two experimental groups in the baseline ( $p = 0.565$ ), and all post-trauma periods



**FIG. 2.** Mean ( $\pm$ SEM) ICP (top) and CPP (bottom) of the sham and trauma groups before and up to 10 h after CCI. The arrow indicates the time-point of CCI. Gray bars represent the pre-selected periods for statistical analysis (2-way repeated measures ANOVA with Student-Newman-Keuls post-hoc test) and include the calculated significance levels between sham and trauma groups. Significant differences between groups at individual time-points are marked by asterisks ( $*p < 0.05$ ).

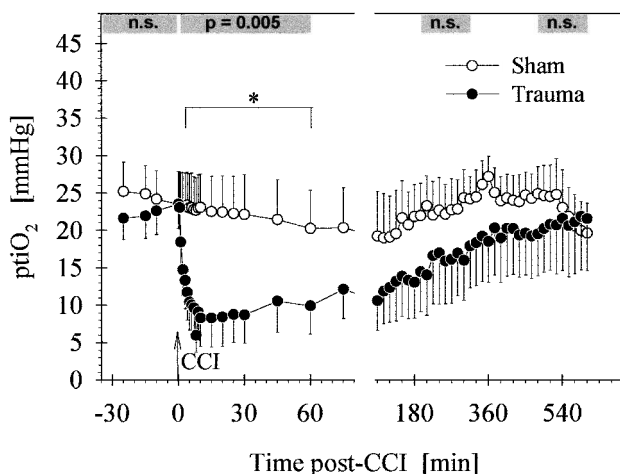
(0.5–60 min:  $p = 0.652$ ; 180 to 300 min:  $p = 0.339$ ; 480–600 min:  $p = 0.500$ ).

**ptiO<sub>2</sub>.** Ipsilateral ptiO<sub>2</sub> values are depicted in Figure 3. Baseline tissue oxygen levels were 25.0  $\pm$  7.1 (ipsilateral) and 32.1  $\pm$  5.5 mm Hg (contralateral) for the sham-operated group and 21.3  $\pm$  7.3 (ipsi) and 34.3  $\pm$  5.0 mm Hg (contra) for the traumatized group. Following CCI, ipsilateral ptiO<sub>2</sub> levels of the trauma group fell rapidly to 6.0  $\pm$  2.3 mm Hg at 8 min post-CCI (contralateral: 24.7  $\pm$  5.8 mm Hg). Thereafter, tissue oxygenation recovered in both hemispheres, finally reaching baseline values after more than 5 h. ptiO<sub>2</sub> values of the sham group remained stable throughout the experiment in both hemispheres (Fig. 3). Groups did not differ significantly during baseline period in both hemispheres. Trauma lowered ptiO<sub>2</sub> significantly in the ipsilateral ( $p = 0.005$ ), but not in the contralateral hemisphere ( $p = 0.607$ ) during the acute post-CCI period (0.5–60 min).

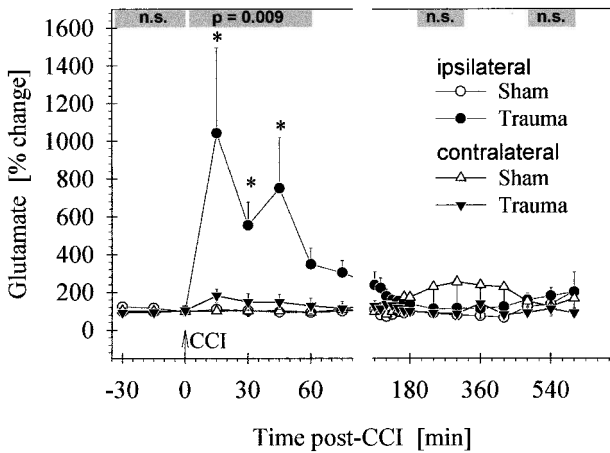
**Glutamate.** Ipsilateral baseline glutamate concentrations in dialysate were 11.0  $\pm$  5.8  $\mu$ M in the sham-operated and 6.1  $\pm$  1.7  $\mu$ M in the traumatized group. Glutamate increased to a maximum of 54.8  $\pm$  21  $\mu$ M at 15 min post-CCI (Sham = 11.8  $\pm$  8  $\mu$ M) following CCI, but decreased thereafter continuously to baseline and sham levels within 2 h. Mean contralateral glutamate val-

ues were much higher in sham (16.4  $\pm$  9.6  $\mu$ M) and trauma animals (33.6  $\pm$  14.9  $\mu$ M), due to three animals which had levels already above 50  $\mu$ M during their stable baseline. Injury impact led to a short-lasting and non-significant contralateral increase of glutamate by 10.0  $\pm$  2.6  $\mu$ M. As shown in Figure 4, statistical analysis of ipsilateral glutamate showed a significant increase in the acute phase (15–60 min post-CCI) following CCI ( $p = 0.009$ ). No significant difference between the sham and trauma group were found during the baseline ( $p = 0.374$ ), intermediate ( $p = 0.212$ ), and late ( $p = 0.793$ ) post-trauma period and during all periods in the contralateral hemisphere.

**Lactate.** Mean baseline lactate levels were 1.57  $\pm$  0.74 mM (sham) and 0.63  $\pm$  0.05 mM (Trauma) in the ipsilateral, and 1.97  $\pm$  0.67 mM (sham) and 1.33  $\pm$  0.24 mM (trauma) in the contralateral hemisphere. Lactate remained stable in sham-operated pigs, reaching 1.66  $\pm$  0.44 mM (ipsi) and 1.85  $\pm$  0.76 mM (contralateral) at 600 min. Traumatic brain injury produced a massive increase from 0.63 to 2.16  $\pm$  0.58 mM within 30 min ipsilaterally, and lactate remained elevated until the end of the experiment (2.19  $\pm$  0.75 mM) at 600 min post-CCI. Contralateral levels increased from 1.33 to 2.13  $\pm$  0.41 mM at 120 min post-CCI, but stayed slightly elevated throughout the experiment when compared to baseline (Fig. 5). Statistical analysis of ipsilateral lactate indicated



**FIG. 3.** Mean ( $\pm$ SEM) ipsilateral ptiO<sub>2</sub> of the sham and trauma group before and after CCI (arrow; see Fig. 2 and method for graph and statistical details;  $*p < 0.05$ ). Note that all ipsilateral post-hoc comparisons of the acute phase (0.5–60 min post-CCI) were significant, except for the 0.5, 1, and 2 min post-CCI time-points. A slight, short-lasting, but not significant decrease was also seen in the contralateral hemisphere.



**FIG. 4.** Mean ( $\pm$ SEM) percent changes from baseline for ipsilateral and contralateral glutamate in dialysate of the sham and trauma groups before and after CCI (arrow; see Fig. 2 and method for graph and statistical details; \* $p < 0.05$ ). Note that all contralateral comparisons between groups were not significant.

no significant difference between the sham and trauma groups in the baseline period ( $-60$  to  $0$  min:  $p = 0.555$ ). However, there was a significant difference between groups ( $p < 0.001$ ) directly following CCI, as well as during the intermediate ( $180$ – $300$  min post-CCI,  $p = 0.005$ ) and late post-CCI period ( $480$ – $600$  min post-CCI,  $p = 0.004$ ).

**Glucose.** Values for glucose in dialysate varied considerably within groups, ranging from  $0.1$  to  $2$  mM. Generally, glucose levels decreased continuously over the time-course of the experiment in all animals and both hemispheres, despite physiological blood sugar levels. Statistical analysis of ipsilateral values revealed no significant difference between groups during baseline ( $p = 0.266$ ), and during the two late post-trauma periods ( $180$ – $300$  min post-CCI:  $p = 0.761$ ;  $480$ – $600$  min post-CCI:  $p = 0.575$ ). CCI injury induced an acute decrease in ipsilateral glucose levels when compared to sham values ( $p = 0.027$ ). No such effect and significance could be observed contralaterally.

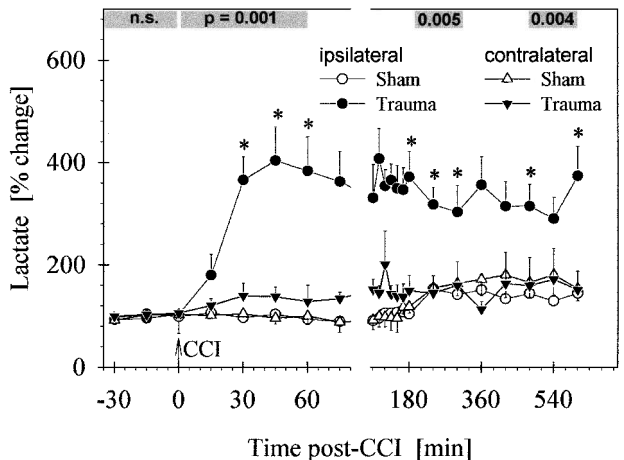
**Lactate/Pyruvate Ratio (LPR).** Mean ipsilateral baseline lactate/pyruvate ratios (LPRs) were  $38.7 \pm 24$  (sham) and  $27.9 \pm 9$  (Trauma). CCI did not change the ratio, since lactate and pyruvate increased simultaneously. Pyruvate increased following CCI from a baseline level of  $46.4 \pm 16$   $\mu$ M to  $165.8 \pm 53$   $\mu$ M at  $75$  min post-CCI. Thereafter, pyruvate started to decrease and lactate remained elevated. Thus,  $2$  h after CCI, LPR increased to  $77.3 \pm 28$ , but recovered within hours to sham levels. Statistical analysis of

LPR indicated no significant difference between the sham and trauma groups in the baseline ( $-60$  to  $0$  min post-CCI:  $p = 0.291$ ) and in all post-trauma periods ( $15$ – $60$  min post-CCI:  $p = 0.164$ ;  $180$ – $300$  min post-CCI:  $p = 0.173$ ;  $480$ – $600$  min post-CCI:  $p = 0.078$ ).

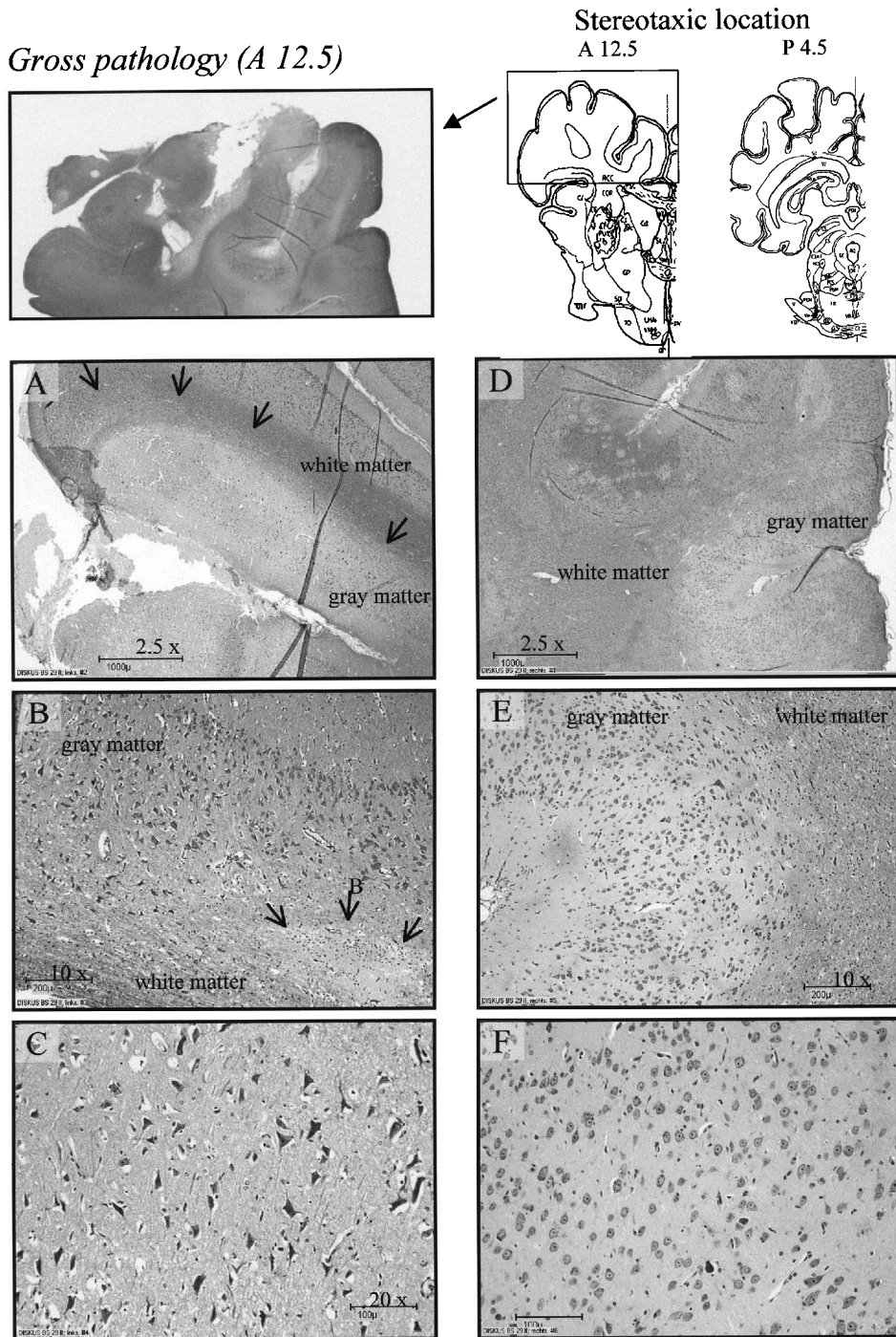
### *Histological Outcome and Its Relationship to Neuromonitoring*

As shown in Figure 6 traumatic brain injury caused hemorrhages, cell swelling and neuronal cell damage/loss beneath the injury site. The ipsilateral injury score was significantly higher following CCI when compared to sham animals and the contralateral hemisphere. Although some tissue damage could be found in the contralateral hemisphere of some traumatized pigs, the contralateral injury score of the sham and trauma groups were comparable (Table 1). Comparing our injury score with the published contusion index (CI) of Adams et al. (1985), using the same sections for analysis, revealed a significant relationship between the two measurements (Spearman correlation coefficient:  $0.942$ ,  $p < 0.001$ ). Similar to the injury index (Table 1), mean ipsilateral ( $9.5 \pm 0.7$ ) and contralateral ( $5.3 \pm 1.1$ ) CI were significantly different from each other ( $p = 0.011$ ).

Analyzing the relationship between histological outcome and neuromonitoring parameters using Spearman rank correlation showed a significant relationship between injury score and glutamate ( $0.842$ ,  $p < 0.001$ ), ICP ( $0.727$ ,  $p = 0.010$ ),  $ptiO_2$  ( $-0.636$ ,  $p = 0.032$ ), or CPP



**FIG. 5.** Mean ( $\pm$ SEM) percent changes from baseline for ipsilateral and contralateral lactate in dialysate of the sham and trauma groups before and after CCI (arrow; see Fig. 2 and method for graph and statistical details; \* $p < 0.05$ ). Note that all contralateral comparisons between groups were not significant ( $p > 0.240$ ).



**FIG. 6.** Gross pathology of the traumatized hemisphere at the stereotaxic location A12.5 and schematic drawings of the two coronal sections used for histological analysis of injury score and contusion index (Top; modified from Felix et al., 1999). The lower panels show ipsilateral (A,B,C) and contralateral (D,E,F) magnifications of cortical gyri within the injured area. The border zone between gray and white matter is marked by arrows and an intraparenchymal bleeding by B. Note that already 12 h post-CCI massive swelling and cell death can be seen in the sections. Although some cells seem to be affected by CCI in the contralateral hemisphere (D–F), most look normal.

TABLE 1. INJURY SCORE OF SHAM-OPERATED AND TRAUMATIZED PIGS 12h AFTER CONTROLLED IMPACT

	Sham		Trauma	
	Ipsilateral	Contralateral	Ipsilateral	Contralateral
Cell injury				
White matter	2.65 ± 0.9	1.75 ± 0.5	5.8 ± 0.9	3.4 ± 1.1
Gray matter	3.75 ± 0.8	4.15 ± 0.9	10.5 ± 1.0	6.4 ± 1.2
Hemorrhage				
White matter	1.05 ± 0.6	0.30 ± 0.2	2.1 ± 0.7	0.7 ± 0.4
Gray matter	0.75 ± 0.3	0.65 ± 0.6	3.9 ± 0.7	0.8 ± 0.5
Injury score				
Sum	82	68.5	267*.#	135

\* $p = 0.005$ , trauma versus sham group.

# $p = 0.01$ , ipsilateral versus contralateral hemisphere of trauma group.

Injury score (total of all given scores/hemisphere and group) and mean scores ( $\pm$  SEM) for both analyzed parameters (cell injury, hemorrhage) in the white and gray matter of the anterior (A12.5 mm) and posterior sections (P4.5 mm) (Felix et al., 1999) from sham-operated ( $n = 5$ ) and traumatized pigs ( $n = 6$ ). Statistical analysis was performed by paired and unpaired  $t$ -test with the total injury score only. Note that comparison of the injury score with a contusion index (Adams et al., 1985) is described in the Results section.

( $-0.627$ ,  $p = 0.035$ ) for the first hour post-CCI. During the second hour after trauma, lactate became related to the injury score ( $0.770$ ,  $p = 0.007$ ), whereas correlation for glutamate ( $0.685$ ,  $p = 0.025$ ) and ICP ( $0.665$ ,  $p = 0.023$ ) were still significant (ptiO<sub>2</sub>:  $-0.582$ ,  $p = 0.056$ ). Between hour 2 and 3 post-CCI, only lactate ( $0.830$ ,  $p < 0.001$ ) and glutamate ( $0.691$ ,  $p = 0.017$ ) were highly correlated with histology (ptiO<sub>2</sub>:  $-0.536$ ,  $p = 0.082$ ). Thereafter ( $>3$  h), no correlation was found.

Analyzing the relationship between histological outcome (injury score) and neuromonitoring parameters using a neuronal network software (NeuroModel<sup>®</sup>) revealed that glutamate (0–60 min post-CCI), ICP (0–60 min post-CCI) and ptiO<sub>2</sub> (60–180 min post-CCI) could best predict histological outcome during the first 3 h following CCI. At later time-points, histological outcome did not correlate with and could not be predicted by any neuromonitoring parameter.

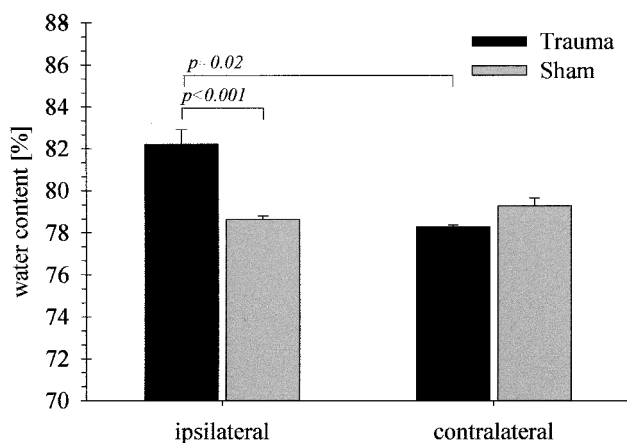
## DISCUSSION

Focal traumatic brain injury (TBI) produces massive pathophysiological changes such as release of glutamate and mediators of cell death, ICP increase, CBF reduction, edema formation, metabolic mismatch between substrate delivery/demand and ionic dysfunction, all of which are factors in the histological and functional outcome. Therefore, the simultaneous monitoring of such changes in severely head-injured patients has been introduced in many neurointensive care units. Although im-

portant pathophysiological mechanisms could be related to the outcome in patients, the interpretation and consequently the use for therapeutical intervention of monitored data has proven to be difficult, mainly due to the variability of brain trauma in humans, catheter placement, and the complexity of tissue reactions to trauma. Thus, the basis for a better understanding of data from patients is a standardized model of TBI which allows extended multi-parametric neuromonitoring comparable to that in patients.

In the present study, pigs have been selected as the species since they have a brain structure with gyri/sulci and a size that is large enough to employ multi-parametric neuromonitoring. In piglets or cats, CCI or fluid percussion injury (FPI) are delivered by using tip sizes of up to 12.67 mm (7 mm indentation) (Duhaime et al., 2000; Durham et al., 2000) or connector diameters of about 10 mm (Brodhun et al., 2001; Zauner et al., 2002), respectively. Considering the brain size of pigs which was about 70 g in our study (cat = 35 g), an impactor tip of 20 mm in diameter, an injury depth of 9 mm and a velocity of 2.6–2.8 m/sec were selected to produce a significant, but unilateral contusion (Fig. 6, Table 1). We found foci of intracranial, subarachnoid hemorrhage, disrupted tissue within the white and gray matter and cell injury underneath the injury site. Due to the relatively early time point of brain removal after CCI, a sharp demarcation between contused and surviving tissue was not possible. Although cellular changes leading to cell death can be detected, distinctive contusion borders might only be seen later than 12 h post-TBI (Brodhun et al., 2001; Duhaime et al., 2000).



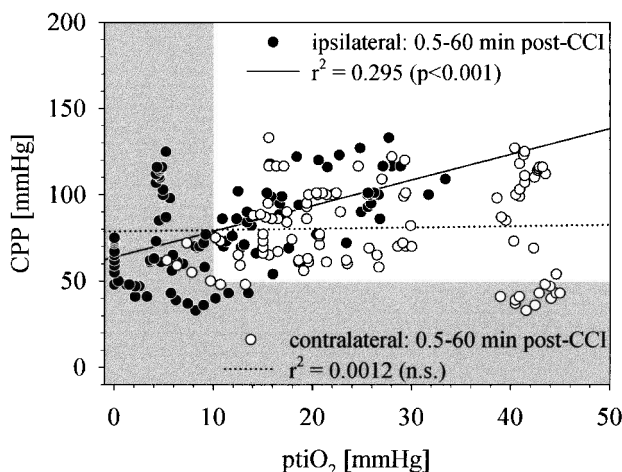


**FIG. 7.** Mean ( $\pm$ SEM) percent hemispheric water content for the sham and trauma groups at 12 h post-CCI. Swelling (%) was  $5.03 \pm 0.87\%$  in the trauma and  $0.84 \pm 0.42\%$  in the sham group ( $p < 0.001$ ). Comparisons were made between groups by unpaired *t*-tests and within groups by paired *t*-tests.

Beside the primary cell damage due to brain deformation itself, a cascade of events is initiated. The first global effect to trauma is characterized by changes in blood pressure, intracranial pressure and consequently cerebral perfusion pressure, which all are factors linked to histological and functional damage in head-injury. Intracranial hypertension develops rapidly after experimental CCI injury (Kroppenstedt et al., 1998, 1999), or severe human brain trauma (Alberico et al., 1987; Barbiro-Micahely and Mayevsky, 2001; Unterberg et al., 1993) and is a good marker for the severity of trauma. The rise of ICP is related to ischemic CPP, high substrate (glucose, oxygen) demand and ionic dysfunction which lead to cell swelling. In patients, maximal ICP levels were generally reached within 3 days, but later secondary peaks have also been reported (Unterberg et al., 1993). Severe FPI in piglets (3.5 atm pulse, 9-mm diameter) produced an acute blood pressure and CPP drop which were accompanied by elevated ICP. In 50% of the investigated animals, FPI led to a secondary and lasting (24h) hypertension (Brodhun et al., 2001). In another piglet study, scaled CCI produced subtle pressure effects only (Duhaim et al., 2000; Durham et al., 2000). However, in both studies considerable histological damage developed within days following injury. In rat CCI models a distinct time course of brain swelling has been elucidated, with maximal edema formation at 24–48 h after trauma (Baskaya et al., 1997; Kochanek et al., 1995; Kroppenstedt et al., 1999; Unterberg et al., 1993). In the present study, ICP and CPP were moderately increased and decreased, respectively, during the first hours after trauma

only. In addition, a significant ipsilateral swelling (5%; Fig. 7) developed within 12 h which was not accompanied by a secondary ICP elevation. These effects suggest that the applied trauma was rather moderate. They also imply that it is important to monitor other parameters which are known to be related to cell death, since a considerable amount of early histological damage was found without severe ischemia or long-lasting critically reduced CBF.

In this respect, tissue oxygen is considered to be an important monitored parameter, since it not only indicates ischemic conditions, but also increased oxygen consumption. Low tissue oxygenation has been reported in animal studies of traumatic brain injury (Zauner et al., 2002) and in severely head injured patients (Bardt et al., 1998; Dings et al., 1996; Kiening et al., 1997; Meixensberger et al., 2001; Valadka et al., 1998a; Valadka et al., 1998b; Van Den Brink et al., 2000; Zauner et al., 1997). Early global or local ischemia following TBI has been considered responsible for this effect due to reduced oxygen supply to the injured tissue (Bouma et al., 1992; Bryan et al., 1995; Schroder et al., 1995). Although in our study 50% of ipsilateral  $ptiO_2$  values in the early post-CCI period (0.5–60 min) were below ischemic thresholds ( $<10$  mm Hg), only 35% of those were associated with CPP below 60 mm Hg ( $<60$  mm Hg; Fig. 8). In addition, low  $ptiO_2$  values were found at normal CPP and vice versa, which is in agreement with patient data, and might lead to a false interpretation during patient management (Bardt et al., 1998; Kiening et al., 1997). It is important to note that readings are not only dependent on



**FIG. 8.** Regression analysis for the trauma group between CPP and the ipsi- and contralateral  $ptiO_2$  during the acute post-CCI period. Note that oxygen consumption did not follow the perfusion pressure contralaterally.

the actual blood flow, but also on the placement of the catheter (white vs. gray matter), small blood clots which disturb oxygen diffusion to the sensor, but also on the activity of the surrounding tissue. For instance, disturbed vasomotor autoregulation found in head-injured patients (Czosnyka et al., 1997) may lead to an increase or decrease (e.g., vasospasm) of tissue oxygen. Positive correlation between blood pressure peaks and ICP which may indicate a loss of vasomotor reactivity was not found at any analyzed time-point in our study. Clausen et al. (2001) demonstrated that mitochondrial dysfunction, which occurs following experimental and human head injury [e.g., (Verweij et al., 1997)], creates elevated tissue oxygen concentration due to decreased oxygen consumption. On the other hand, hyperglycolysis is known to be induced by TBI (Andersen and Marmarou, 1992; Bergsneider et al., 2000; Bergsneider et al., 1997; Levasseur et al., 2000) causing excessive oxygen consumption and consequently low tissue oxygenation.

Therefore, the combined monitoring of tissue oxygen and biochemical changes of lactate and pyruvate, both products of cellular glycolysis, is indicated and could shed some light on the underlying pathophysiological processes. Meixensberger et al. (2001) found a significant correlation between  $ptiO_2$  and the lactate-to-pyruvate (LPR) ratio which is considered to be a marker of ischemia (Meixensberger et al., 2001). Following severe FPI (2.7 atm) in cats, however,  $ptiO_2$  immediately dropped, whereas LPR did not change dramatically, neither after FPI nor after superimposing arterial hypoxia (Zauner et al., 2002). The authors argued that this was due to a lack of severe ischemia which would also explain our data. LPR was only slightly elevated following CCI and did not correlate with low  $ptiO_2$  or histological outcome. In the early phase after injury, more than 50% of low  $ptiO_2$  values were associated with normal LPR (<40). Thus, the absence of severe ischemia but long-lasting elevated lactate production may point towards induced hypermetabolism (Alessandri et al., 1999; Andersen and Marmarou, 1992) Massive accumulation of lactate changes the intra- and extracellular acid-base balance, creates lactic acidosis and low brain pH (Landolt et al., 1994; Zauner et al., 1997). Recently, high lactate concentrations during the first hours after TBI have been linked to poor outcome in patients (Goodman et al., 1999; Zauner et al., 1997). This massive lactate production can be driven by anaerobic conditions in the brain (ischemia, hypoxia), but is also coupled to the release and uptake of glutamate (Alessandri et al., 1999; Fray et al., 1996). If not released in physiological concentrations, glutamate becomes a known excitotoxic neurotransmitter which produces brain lesions in rats (Alessandri et al., 1996; Ros et al., 2001) and is linked to poor outcome of se-

verely head-injured patients (Alessandri and Bullock, 1998; Bullock et al., 1998). In general, CCI causes a rather short-lasting glutamate increase in animal studies [e.g., (Palmer et al., 1993)], although clinical reports showed long-lasting elevation (Bullock et al., 1995). CCI in pigs also produced a short-term increase in extracellular glutamate (Fig. 4), but a prolonged lactate production (Fig. 5). Despite the known interaction of glutamate with glycolysis and lactate production, no correlation with each other was found at any time-point, which is due to the distinct time-pattern of both parameters. Except for lactate, all changes found in the neuromonitoring parameters normalized within hours following moderate CCI. Expecting this time-course in patients, monitoring would start at a time-point indicating normal brain biochemistry and oxygen supply to the clinician, although damaging processes had already been initiated. The significant correlation of ICP, CPP, glutamate, lactate and  $ptiO_2$  with the injury score, a histological outcome parameter, clearly demonstrates that early events after CCI translate into good or poor outcome. We suggest that the rather moderate contusion in our porcine model induced a complex interaction of pathophysiological parameters leading to a wide-spread cortical damage. ICP, glutamate and  $ptiO_2$  seemed to be early markers of histological outcome, whereas lactate correlated better at later time-periods. This complex pattern was tested and supported by analyzing our data using a neuronal network software which calculated an order of outcome prediction for all parameters at any chosen time-point. With the few data points from our study the program revealed a high prediction sensitivity for glutamate and ICP early after CCI and for  $ptiO_2$  at later time-points. However, good correlation with and prediction of histological outcome was limited to the first couple of hours which might be due to the moderate injury. However, such early changes cannot be measured in patients after TBI and will therefore not be usable to guide therapy. Thus, more severe contusions and longer observation periods will be necessary to compare with long-lasting or secondary changes seen in severely head-injured patients. On the other hand, our experimental approach enables us to apply therapeutic measures and to follow the induced effects on neuromonitoring parameters as well as on histology.

The present study showed that a standardized injury to a large brain induces well-known pathophysiological processes which are comparable to those found in the clinical routine. The data indicate that despite mild ischemia, a complex interaction of ICP, CPP, glutamate, lactate and  $ptiO_2$  is playing a crucial role in the development of brain lesion. They also support the view that more than one parameter should be assessed by neu-

romonitoring in order to allow the distinction between different pathophysiological conditions in the brain. Following moderate cortical contusion, tissue oxygen, glutamate, and lactate seem to be ideal candidates for extended neuromonitoring. Studies elucidating the complex interaction of neuromonitoring parameters following a controlled injury may enable us to prevent false data interpretation in patients and to translate therapeutical effects into clinical use.

## ACKNOWLEDGMENTS

We thank Drs. A. Unterberg and B. Hölper as well as the company Axel Semrau for supporting us with the CMA/600 enzymatic analyzer. We are also grateful for help to cover the night shifts by Ali Barhoum. This project was supported by a grant from the University of Mainz (Schwerpunkt Neurowissenschaft).

## REFERENCES

- ADAMS, J.H., DOYLE, D., GRAHAM, D.I., et al. (1985). The contusion index: a reappraisal in human and experimental non-missile head injury. *Neuropathol. Appl. Neurobiol.* **11**, 299–308.
- ALBERICO, A.M., WARD, J.D., CHOI, S.C., et al. (1987). Outcome after severe head injury. Relationship to mass lesions, diffuse injury, and ICP course in pediatric and adult patients. *J. Neurosurg.* **67**, 648–656.
- ALESSANDRI, B., and BULLOCK, R. (1998). Glutamate and its receptors in the pathophysiology of brain and spinal cord injuries. *Prog. Brain Res.* **116**, 303–330.
- ALESSANDRI, B., DOPPENBERG, E., BULLOCK, R., et al. (1999). Glucose and lactate metabolism after severe human head injury: influence of excitatory neurotransmitters and injury type. *Acta Neurochir. Suppl. (Wien)* **75**, 21–24.
- ALESSANDRI, B., DOPPENBERG, E., ZAUNER, A., et al. (1999). Evidence for time-dependent glutamate-mediated glycolysis in head-injured patients: a microdialysis study. *Acta Neurochir. Suppl. (Wien)* **75**, 25–28.
- ALESSANDRI, B., LANDOLT, H., LANGEMANN, H., et al. (1996). Application of glutamate in the cortex of rats: a microdialysis study. *Acta Neurochir. Suppl. (Wien)* **67**, 6–12.
- ANDERSEN, B.J., and MARMAROU, A. (1992). Post-traumatic selective stimulation of glycolysis. *Brain Res.* **585**, 184–189.
- BARBIRO-MICAHELY, E., and MAYEVSKY, A. (2001). Multiparametric monitoring of brain under elevated intracranial pressure in a rat model. *J. Neurotrauma* **18**, 711–725.
- BARDT, T.F., UNTERBERG, A.W., HARTL, R., et al. (1998). Monitoring of brain tissue PO<sub>2</sub> in traumatic brain injury: effect of cerebral hypoxia on outcome. *Acta Neurochir. Suppl. (Wien)* **71**, 153–156.
- BASKAYA, M.K., RAO, A.M., DOGAN, A., et al. (1997). The biphasic opening of the blood–brain barrier in the cortex and hippocampus after traumatic brain injury in rats. *Neurosci. Lett.* **226**, 33–36.
- BERGSNEIDER, M., HOVDA, D.A., LEE, S.M., et al. (2000). Dissociation of cerebral glucose metabolism and level of consciousness during the period of metabolic depression following human traumatic brain injury. *J. Neurotrauma* **17**, 389–401.
- BERGSNEIDER, M., HOVDA, D.A., SHALMON, E., et al. (1997). Cerebral hyperglycolysis following severe traumatic brain injury in humans: a positron emission tomography study. *J. Neurosurg.* **86**, 241–251.
- BOUMA, G.J., MUIZELAAR, J.P., STRINGER, W.A., et al. (1992). Ultra-early evaluation of regional cerebral blood flow in severely head-injured patients using xenon-enhanced computerized tomography. *J. Neurosurg.* **77**, 360–368.
- BRODHUN, M., FRITZ, H., WALTER, B., et al. (2001). Immunomorphological sequelae of severe brain injury induced by fluid-percussion in juvenile pigs—effects of mild hypothermia. *Acta Neuropathol. (Berl.)* **101**, 424–434.
- BRYAN, R.M., JR., CHERIAN, L., and ROBERTSON, C. (1995). Regional cerebral blood flow after controlled cortical impact injury in rats. *Anesth. Analg.* **80**, 687–695.
- BULLOCK, R., ZAUNER, A., MYSEROS, J.S., et al. (1995). Evidence for prolonged release of excitatory amino acids in severe human head trauma. Relationship to clinical events. *Ann. NY Acad. Sci.* **765**, 290–298.
- BULLOCK, R., ZAUNER, A., TSUJI, O., et al. (1995). Patterns of excitatory amino acid and ionic flux after severe human head trauma. in: T. Tsubokawa, A. Marmarou, C. Robertson, et al. (eds.), *Neuromonitoring in the Intensive Care Unit: Microdialysis, Jugular Venous Oximetry, Near-Infrared Spectroscopy*. Springer-Verlag: Tokyo, pps. 64–71.
- BULLOCK, R., ZAUNER, A., WOODWARD, J.J., et al. (1998). Factors affecting excitatory amino acid release following severe human head injury. *J. Neurosurg.* **89**, 507–518.
- CLAUSEN, T., ZAUNER, A., LEVASSEUR, J.E., et al. (2001). Induced mitochondrial failure in the feline brain: implications for understanding acute post-traumatic metabolic events. *Brain Res.* **908**, 35–48.
- CZOSNYKA, M., SMIELEWSKI, P., KIRKPATRICK, P., et al. (1997). Continuous assessment of the cerebral vasomotor reactivity in head injury. *Neurosurgery* **41**, 11–19.
- DINGS, J., MEIXENSBERGER, J., AMSCHLER, J., et al. (1996). Brain tissue pO<sub>2</sub> in relation to cerebral perfusion pressure, TCD findings and TCD-CO<sub>2</sub>-reactivity after severe head injury. *Acta Neurochir. (Wien)* **138**, 425–434.

- DIXON, C.E., CLIFTON, G.L., LIGHTHALL, J.W., et al. (1991). A controlled cortical impact model of traumatic brain injury in the rat. *J. Neurosci. Methods* **39**, 253–262.
- DUHAIME, A.C., MARGULIES, S.S., DURHAM, S.R., et al. (2000). Maturation-dependent response of the piglet brain to scaled cortical impact. *J. Neurosurg.* **93**, 455–462.
- DURHAM, S.R., RAGHUPATHI, R., HELFAER, M.A., et al. (2000). Age-related differences in acute physiologic response to focal traumatic brain injury in piglets. *Pediatr. Neurosurg.* **33**, 76–82.
- FELIX, B., LEGER, M.E., ALBE-FESSARD, D., et al. (1999). Stereotaxic atlas of the pig brain. *Brain Res. Bull.* **49**, 1–137.
- FRAY, A.E., FORSYTH, R.J., BOUTELLE, M.G., et al. (1996). The mechanisms controlling physiologically stimulated changes in rat brain glucose and lactate: a microdialysis study. *J. Physiol.* **496**, 49–57.
- GOODMAN, J.C., GOPINATH, S.P., VALADKA, A.B., et al. (1996). Lactic acid and amino acid fluctuations measured using microdialysis reflect physiological derangements in head injury. *Acta Neurochir. Suppl. (Wien)* **67**, 37–39.
- GOODMAN, J.C., VALADKA, A.B., GOPINATH, S.P., et al. (1999a). Simultaneous measurement of cortical potassium, calcium, and magnesium levels measured in head injured patients using microdialysis with ion chromatography. *Acta Neurochir. Suppl. (Wien)* **75**, 35–37.
- GOODMAN, J.C., VALADKA, A.B., GOPINATH, S.P., et al. (1999b). Extracellular lactate and glucose alterations in the brain after head injury measured by microdialysis. *Crit. Care Med.* **27**, 1965–1973.
- HILLERED, L., PERSSON, L., PONTEN, U., et al. (1990). Neurometabolic monitoring of the ischaemic human brain using microdialysis. *Acta Neurochir. (Wien)* **102**, 91–97.
- KATAYAMA, Y., BECKER, D.P., TAMURA, T., et al. (1990). Massive increases in extracellular potassium and the indiscriminate release of glutamate following concussive brain injury. *J. Neurosurg.* **73**, 889–900.
- KEMPSKI, O., VON ANDRIAN, U., SCHURER, L., et al. (1990). Intravenous glutamate enhances edema formation after a freezing lesion. *Adv. Neurol.* **52**, 219–223.
- KIENING, K.L., HARTL, R., UNTERBERG, A.W., et al. (1997). Brain tissue pO<sub>2</sub>-monitoring in comatose patients: implications for therapy. *Neurol. Res.* **19**, 233–240.
- KOCHANEK, P.M., MARION, D.W., ZHANG, W., et al. (1995). Severe controlled cortical impact in rats: assessment of cerebral edema, blood flow, and contusion volume. *J. Neurotrauma* **12**, 1015–1025.
- KROPFENSTEDT, S.N., SCHNEIDER, G.H., THOMALE, U.W., et al. (1998). Protective effects of aptiganel HCl (Cerestat) following controlled cortical impact injury in the rat. *J. Neurotrauma* **15**, 191–197.
- KROPFENSTEDT, S.N., STROOP, R., KERN, M., et al. (1999). Lubeluzole following traumatic brain injury in the rat. *J. Neurotrauma* **16**, 629–637.
- LANDOLT, H., LANGEMANN, H., MENDELWITSCH, A., et al. (1994). Neurochemical monitoring and on-line pH measurements using brain microdialysis in patients in intensive care. *Acta Neurochir. Suppl. (Wien)* **60**, 475–478.
- LEVASSEUR, J.E., ALESSANDRI, B., REINERT, M., et al. (2000). Fluid percussion injury transiently increases then decreases brain oxygen consumption in the rat. *J. Neurotrauma* **17**, 101–112.
- MEIXENSBERGER, J., KUNZE, E., BARCSAY, E., et al. (2001). Clinical cerebral microdialysis: brain metabolism and brain tissue oxygenation after acute brain injury. *Neurol. Res.* **23**, 801–806.
- NARAYAN, R.K., MICHEL, M.E., ANSELL, B., et al. (2002). Clinical trials in head injury. *J. Neurotrauma* **19**, 503–557.
- PALMER, A., MARION, D., BOTSCHHELLER, M., et al. (1993). Traumatic brain injury-induced excitotoxicity assessed in a controlled cortical impact model. *J. Neurochem.* **61**, 2015–2024.
- REINERT, M., KHALDI, A., ZAUNER, A., et al. (2000). High level of extracellular potassium and its correlates after severe head injury: relationship to high intracranial pressure. *J. Neurosurg.* **93**, 800–807.
- ROS, J., PECINSKA, N., ALESSANDRI, B., et al. (2001). Lactate reduces glutamate-induced neurotoxicity in rat cortex. *J. Neurosci. Res.* **66**, 790–794.
- SCHRODER, M.L., MUIZELAAR, J.P., BULLOCK, M.R., et al. (1995). Focal ischemia due to traumatic contusions documented by stable xenon-CT and ultrastructural studies. *J. Neurosurg.* **82**, 966–971.
- STOCCHETTI, N., PENNY, K.I., DEARDEN, M., et al. (2001). Intensive care management of head-injured patients in Europe: a survey from the European brain injury consortium. *Intens. Care Med.* **27**, 400–406.
- UNTERBERG, A., KIENING, K., SCHMIEDEK, P., et al. (1993). Long-term observations of intracranial pressure after severe head injury. The phenomenon of secondary rise of intracranial pressure. *Neurosurg. (Balt.)* **32**, 17–24.
- UNTERBERG, A.W., SAKOWITZ, O.W., SARAFZADEH, A.S., et al. (2001). Role of bedside microdialysis in the diagnosis of cerebral vasospasm following aneurysmal subarachnoid hemorrhage. *J. Neurosurg.* **94**, 740–749.
- VAJKOCZY, P., ROTH, H., HORN, P., et al. (2000). Continuous monitoring of regional cerebral blood flow: experimental and clinical validation of a novel thermal diffusion microprobe. *J. Neurosurg.* **93**, 265–274.
- VALADKA, A.B., GOODMAN, J.C., GOPINATH, S.P., et al. (1998a). Comparison of brain tissue oxygen tension to

- microdialysis-based measures of cerebral ischemia in fatally head-injured humans. *J. Neurotrauma* **15**, 509–519.
- VALADKA, A.B., GOPINATH, S.P., CONTANT, C.F., et al. (1998b). Relationship of brain tissue PO<sub>2</sub> to outcome after severe head injury. *Crit. Care Med.* **26**, 1576–1581.
- VAN DEN BRINK, W.A., VAN SANTBRINK, H., STEYERBERG, E.W., et al. (2000). Brain oxygen tension in severe head injury. *Neurosurgery* **46**, 868–876.
- VAN SANTBRINK, H., MAAS, A.I., and AVEZAAT, C.J. (1996). Continuous monitoring of partial pressure of brain tissue oxygen in patients with severe head injury. *Neurosurgery* **38**, 21–31.
- VATH, A., MEIXENSBERGER, J., DINGS, J., et al. (2000). Prognostic significance of advanced neuromonitoring after traumatic brain injury using neural networks. *Zentralbl. Neurochir.* **61**, 2–6.
- VERWEIJ, B.H., MUIZELAAR, J.P., VINAS, F.C., et al. (1997). Mitochondrial dysfunction after experimental and human brain injury and its possible reversal with a selective N-type calcium channel antagonist (SNX-111). *Neurol. Res.* **19**, 334–339.
- ZAUNER, A., BULLOCK, R., DI, X., et al. (1995). Brain oxygen, CO<sub>2</sub>, pH, and temperature monitoring: evaluation in the feline brain. *Neurosurgery* **37**, 1168–1176.
- ZAUNER, A., CLAUSEN, T., ALVES, O.L., et al. (2002). Cerebral metabolism after fluid-percussion injury and hypoxia in a feline model. *J. Neurosurg.* **97**, 643–649.
- ZAUNER, A., DOPPENBERG, E., WOODWARD, J.J., et al. (1997a). Multiparametric continuous monitoring of brain metabolism and substrate delivery in neurosurgical patients. *Neurol. Res.* **19**, 265–273.
- ZAUNER, A., DOPPENBERG, E.M., WOODWARD, J.J., et al. (1997b). Continuous monitoring of cerebral substrate delivery and clearance: initial experience in 24 patients with severe acute brain injuries. *Neurosurgery* **41**, 1082–1091.

Address reprint requests to:

*Beat Alessandri, Ph.D.*

*Institute for Neurosurgical Pathophysiology*

*University of Mainz*

*Langenbeckstrasse 1*

*Bldg. 505/U180*

*D-55101 Mainz, Germany*

*E-mail: beat.alessandri@uni-mainz.de*