

Blood Flow and Vascular Permeability During Motor Dysfunction in a Rabbit Model of Spinal Cord Ischemia

Thomas P. Jacobs, PhD; Oliver Kempfski, MD, PhD; David McKinley, MD; Andrew J. Dutka, MD; John M. Hallenbeck, MD; and Giora Feuerstein, MD

Background and Purpose: Delayed deterioration of neurological function after central nervous system ischemia is a well-documented clinical problem. The purpose of our study was to elucidate the role of spinal cord blood flow and spinal cord-blood barrier integrity in the evolution of delayed neurological deterioration after transient spinal cord ischemia in rabbits.

Methods: Anesthetized rabbits were subjected to lumbar spinal cord ischemia (25 minutes) and variable periods of reperfusion (30 minutes to 48 hours after ischemia). Regional spinal cord blood flow was monitored by carbon-14-labeled iodoantipyrine autoradiography; vascular permeability was assessed by quantitative microhistofluorescence of Evans blue-albumin in frozen sections of spinal cord. Hindlimb motor function was assessed by standard scoring system and tissue edema by wet/dry weight method.

Results: Hindlimb motor function indicated complete paralysis during ischemia and partial gradual recovery upon reperfusion (up to 8 hours), followed by progressive deterioration to severe deficits over 48 hours. Severe vascular permeability disruption was noticed early (30 minutes) after reperfusion, but almost complete recovery reestablished at 8 hours was followed by a secondary progressive increase in vascular permeability. Blood flow was reduced by 20–30% ($p < 0.01$) 4 hours after ischemia in the gray matter, but hyperemia (200–300%, $p < 0.01$) was observed 12–24 hours after ischemia. Spinal cord water content increased by 5.7% ($p < 0.05$) 24 hours after ischemia.

Conclusions: This study demonstrates that delayed neurological and motor deterioration after spinal cord ischemia is associated with severe progressive breakdown of spinal cord-blood barrier integrity that develops late (hours) after the injury. Our data suggest that no ischemic insult in early or late reperfusion is associated with delayed motor deterioration. (*Stroke* 1992;23:367–373)

KEY WORDS • blood-brain barrier • spinal cord • rabbits

Our laboratory as well as others has studied a highly reproducible model of rabbit spinal cord ischemia as a model of progressing stroke (i.e., stroke-in-evolution) in humans.^{1,2} Within 4 hours of reperfusing the ischemic spinal cord, 70% of the rabbits regained substantial motor function, which subsequently deteriorated to complete paralysis during the next 20 hours.³ In the same model, the temporal pattern of edema correlated well with the changes in

motor function. Although much progress has been made in understanding the pathophysiology of brain ischemia, questions remain as to the underlying cause of edema and its effect on delayed motor dysfunction.

It is well known that ischemia will increase vascular permeability. Ischemic damage to the blood-brain barrier (BBB) develops at different times, depending on the duration of the ischemic insult.^{4,5} A biphasic opening of the BBB to proteins was observed at 15 minutes and 5 hours after 60 minutes of middle cerebral artery occlusion in the lightly anesthetized cat.⁶ However, breakdown of the BBB was seen as early as 1 minute after 28 minutes of ischemia in a rat unilateral common carotid occlusion model.⁷ In a unilateral carotid occlusion model in the Mongolian gerbil, 30 minutes of ischemia followed by reperfusion did not produce BBB damage until 20 hours later.⁸ These studies suggest that vasogenic edema can considerably influence the dynamics of ischemic injury in the central nervous system (CNS).^{6,9} Although the temporal aspects of BBB function after ischemia have been studied in several models,^{6,8} the relation of blood barrier integrity to CNS function has not been reported.

Deterioration of motor function after ischemia may also be the result of changes in blood flow.⁴ However, the data on cerebral blood flow (CBF) changes after

From the National Institutes of Health (T.P.J.), the Neurology Clinic, National Naval Medical Center (A.J.D.), and the National Institute of Neurological Disorders and Stroke (J.M.H.), Bethesda, Md.; Klinikum Der Johannes Gutenberg-Universität, Institut f. Neurochirurgische Pathophysiologie (O.K.), Mainz, FRG; and the Department of Pediatrics, Geisinger Medical Center (D.M.), Danville, and the Division of Pharmacology, SmithKline Beecham Pharmaceuticals (G.F.), King of Prussia, Pa.

Supported in part by the American Heart Association (Contract No. G29218).

The opinions or assertions contained herein are the private ones of the authors and are not to be construed as official or reflecting the views of the Department of Defense or the Uniformed Services University of the Health Sciences.

Address for correspondence: Giora Feuerstein, MD, Division of Pharmacology, SmithKline Beecham Pharmaceuticals, PO Box 1539, UW2511, King of Prussia, PA 19406-0939.

Received May 17, 1990; accepted October 24, 1991.

single-artery occlusion in the CNS are variable.⁴ The variability may reflect the differences in methodology, animal species, age, and heterogeneity of CBF.⁴⁻⁶ For example, deterioration of function may be the result of delayed postischemic hypoperfusion.⁷ Generally, CBF is decreased after reperfusion in regions showing histological changes; however, CBF and histology do not always correlate well.⁸ Also, hyperemia has been found in humans during the 24-hour period after ischemic brain injury.⁹

To further understand the potential pathophysiological mechanisms underlying deteriorating motor function after ischemia, the present study was designed to explore the potential role of spinal cord blood flow and spinal cord-blood barrier permeability changes during progressive motor dysfunction after transient spinal cord ischemia. In this model, transient ischemia to the lumbar spinal cord of rabbits is produced by occlusion of the lower abdominal aorta.^{3,10} This model provides a unique opportunity to study motor function in the conscious state during ischemic and reperfusion periods.

Materials and Methods

The experiments described herein were conducted according to the principles set forth in the "Guide for the Care and Use of Laboratory Animals" from the Institute of Laboratory Animals, National Research Council publication no. NIH 85-17. Any procedure that could induce discomfort in the rabbits was performed under general anesthesia. New Zealand albino rabbits (Hazelton Laboratories, York, Pa.) weighing 2.0–2.5 kg were surgically prepared and subjected to an experimental spinal cord ischemic protocol as described elsewhere.^{3,11}

Hindlimb motor function was graded at hourly intervals during the 24-hour reperfusion period as previously described.³ Two investigators performed the evaluations independently. Water content in specific spinal cord regions was assessed by the wet/dry weight method.¹² Vascular permeability to proteins was assessed using Evans blue-albumin as a tracer. Evans blue (Sigma Chemical Co., St. Louis, Mo.) was dissolved in 1.5% bovine serum albumin (Sigma) in 0.9% NaCl to a final concentration of 2 g/100 ml. Thirty minutes before the rabbits were killed, 10 ml/kg of the Evans blue-albumin solution was infused intravenously within 5 minutes. The rabbits were then injected with sodium pentobarbital (100 mg/kg i.v.) and immediately perfused through the heart with 0.9% saline followed by 10% phosphate-buffered formalin (pH 7.4). The spinal cords were removed, frozen on dry ice, sealed in aluminum foil, and stored at -70°C . Within 3 weeks, spinal cords were sectioned (10 μm) using a freezing microtome at -20°C and kept frozen and sealed in a light-tight container before measurement of dye fluorescence.

The histofluorescence of the Evans blue-albumin complex was quantified using a computerized photometry system (model USMP50, Carl Zeiss, Inc., New York). Histofluorescence in different groups of rabbits subjected to 25 minutes of ischemia followed by various periods of reperfusion was compared with that in sham-operated controls. An epifluorescence microscope was equipped with an HBO 100-W mercury vapor illuminator and filters (BP546, FT580, LP590, 50%ND, and RS) were used for optimal excitation and detection of emis-

sion of Evans blue fluorescence.¹³ The instrument was calibrated using Evans blue-albumin standards. A linear relation ($r=0.998$) was observed between fluorescence and amounts of Evans blue between 20 and 620 $\mu\text{g}\%$. The photometer was calibrated for 100% intensity at 160 $\mu\text{g}\%$ Evans blue because pilot studies never yielded amounts >120 $\mu\text{g}\%$. Five anatomic sites were identified with transmitted light to minimize photobleaching and to keep the investigator unbiased. The histofluorescence of individual anatomic regions was then recorded at five sampling sites and the values averaged. Tissue was exposed to light for <2 seconds with shutters set to illuminate a 300- μm -wide circular field at each site.

Spinal cord blood flow was measured by the carbon-14-labeled iodoantipyrine (IAP) autoradiographic method previously described,¹⁴ with only minor modifications. In brief, PE-50 catheters were placed in the medial ear artery and vein to sample isotope concentration and infusion of [^{14}C]IAP (New England Nuclear, Boston, Mass.), respectively. At a predetermined reperfusion time, we infused 70 $\mu\text{Ci}/\text{kg}$ [^{14}C]IAP i.v. over a 60-second period while adjusting the infusion rate every 10 seconds from 2.2 to 120 ml/min. Arterial blood samples were collected at 5-second intervals on glass microfiber filter discs (#GF/B, Whatman, Inc., Clifton, N.J.) and mixed with 10 ml scintillation fluid (Redisolv, Beckman Inc., Palo Alto, Calif.).

After the 60-second infusion period, spinal cord blood flow was immediately terminated by simultaneous injection of a lethal dose of pentobarbitone and severing of the aorta by pulling a preimplanted steel ligature. The spinal cord was extruded from the spinal canal, frozen in isopentane cooled by dry ice, and sectioned (20 μm). The dried sections were placed in contact with roentgenographic film (#SB-5, Kodak, Rochester, N.Y.) in a standard x-ray cassette and incubated for 5 days. The films were developed, and the tissue concentration of [^{14}C]IAP was determined with a densitometer (model #TD502, Mid Atlantic Film Inc., Baltimore, Md.) as previously reported.¹⁴

Data presented in text and figures are mean \pm SEM values for the indicated number of animals. Spinal cord blood flow, vascular resistance, and the amount of tissue Evans blue-albumin were compared with control animals by the Kruskal-Wallis analysis of variance followed by the Mann-Whitney U test.¹⁵ Spinal cord blood flow, tissue water content, and the amount of tissue Evans blue-albumin in hopping (neurological score of 5, 4, or 3) and nonhopping rabbits (neurological score of 2, 1, or 0) were compared by the Mann-Whitney U test. Values for the above statistics were considered significant at the $p < 0.05$ level.

Results

The pattern of hindlimb motor function changes were similar to our previous studies during the 24-hour reperfusion period after spinal cord ischemia.³ Maximal function returned in all rabbits at approximately 4 hours after reperfusion (Figures 1A and 1B). The recovery phase was followed by secondary deterioration, as previously shown.³

Twenty-four hours after reperfusion, tissue water content increased 5.7% in the ventral gray ($81.9 \pm 1.4\%$,

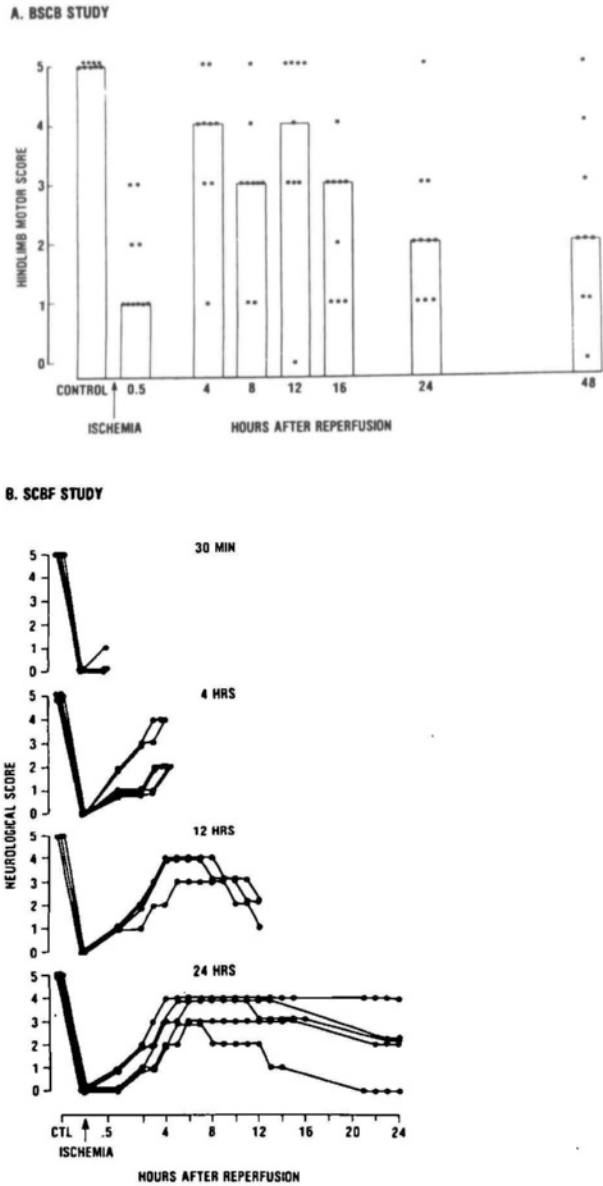


FIGURE 1. Panel A: Effects of 25-minute aortic occlusion on hindlimb motor function in rabbits during 48 hours after ischemia in blood-spinal cord barrier (BSCB) study. Motor function was evaluated by an ordinal scoring method: 0, complete paralysis; 1, minimal functional movement, severe paresis; 2, functional movement present, cannot hop spontaneously or in response to provocation; 3, hopping but ataxia and paresis present; 4, hopping minimally impaired; and 5, normal. Dots, individual animals' hindlimb function scores; bars, median hindlimb score; NL, normal functional score before ischemia. Panel B: Effects of 25-minute aortic occlusion on hindlimb motor function in rabbits during 24 hours after ischemia in spinal cord blood flow (SCBF) study. Motor function was evaluated by the above ordinal scoring method. Each curve represents an individual animal's hindlimb function scores. Dots indicate hindlimb score; last dot on each curve indicates when blood flow values were determined. CTL, control motor function score in rabbits before aortic occlusion.

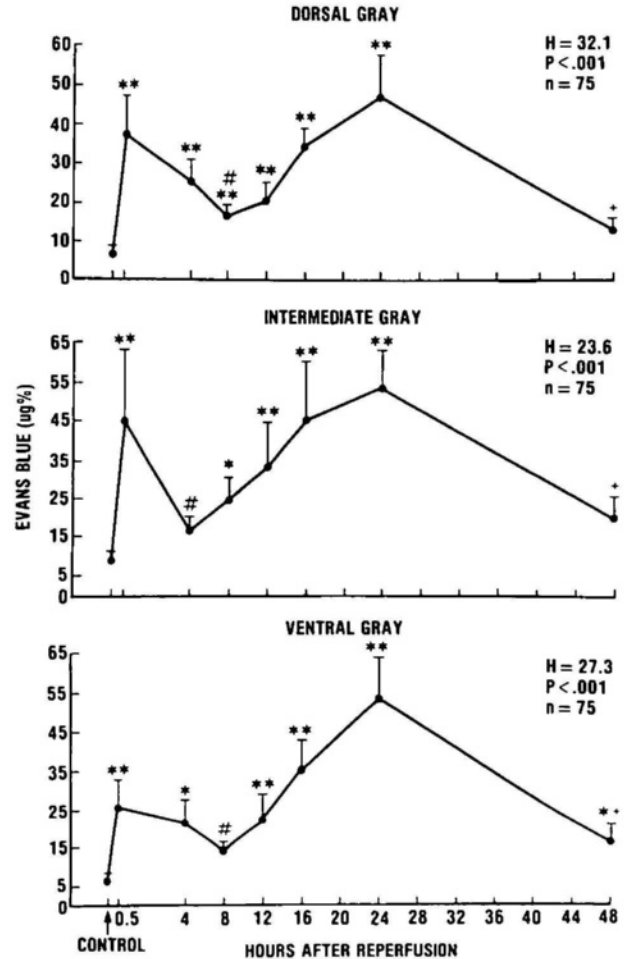


FIGURE 2. Blood-spinal cord barrier permeability to proteins determined in gray matter of rabbit lumbar spinal cord subjected to 25 minutes of ischemia. Protein extravasation was measured by fluorescence photometry of Evans blue-albumin. Zero hour indicates control group. Evans blue-albumin significantly different from controls by Kruskal-Wallis analysis of variance followed by Mann-Whitney U test, * $p < 0.05$ and ** $p < 0.01$; +significant differences at $p < 0.01$ compared with 24-hour levels; #significant differences at $p < 0.05$ compared with 30-minute levels.

$n=8$) and 2.4% in ventral white matter regions ($71.0 \pm 1.2\%$, $n=8$) compared with the respective controls ($76.3 \pm 0.7\%$, $n=11$, $p < 0.005$; $68.6 \pm 0.5\%$, $n=11$, $p < 0.01$, respectively). Also, nonhopping rabbits (motor scores 0, 1, 2) had a 7.7% increase in tissue water content in ventral gray ($84.3 \pm 1.4\%$, $n=5$) and a 4.9% increase in ventral white matter regions (73.2 ± 1.0 , $n=5$) compared with hopping rabbits ($76.6 \pm 0.6\%$, $n=14$, $p < 0.001$; $68.3 \pm 0.4\%$, $n=14$, $p < 0.002$, respectively). Earlier studies reported that a 1% increase in tissue water content was equivalent to tissue swelling of 5.6% and 3.0% in gray and white matter, respectively.^{16,17}

An increase in permeability to Evans blue-albumin was observed in ventral gray, intermediate gray, and dorsal gray (Figure 2), and in ventral white and lateral white matter regions (Figure 3) 30 minutes after reperfusion. The extravasation of Evans blue-albumin at this time was localized to the perivascular space and adjacent tissue, which produced a patchy appearance in gray

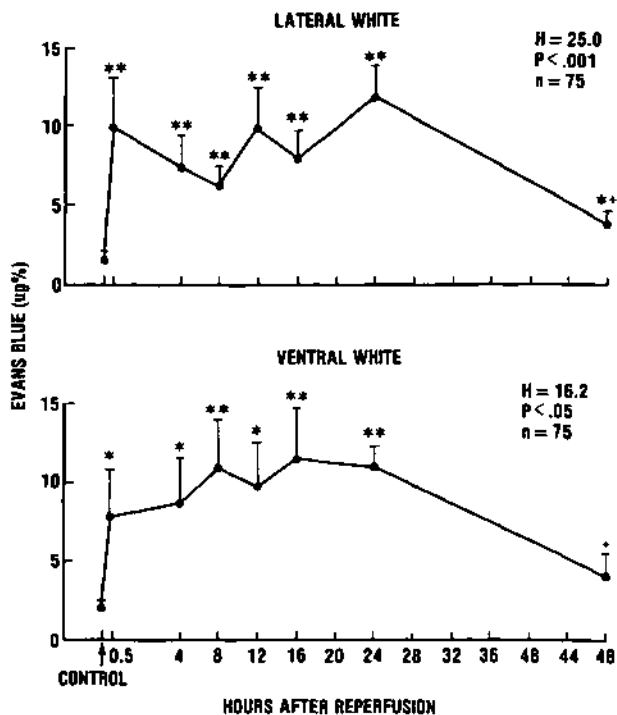


FIGURE 3. Blood-spinal cord barrier permeability to proteins determined in white matter of rabbit lumbar spinal cord subjected to 25 minutes of ischemia. Protein extravasation was measured by fluorescence photometry of Evans blue-albumin. Zero hour indicates control group. Evans blue-albumin significantly different from controls by Kruskal-Wallis analysis of variance followed by Mann-Whitney U test, * $p < 0.05$ and ** $p < 0.01$; *significant differences at $p < 0.01$ compared with 24-hour levels.

and white matter. At 4 hours of reperfusion, in the dorsal, ventral, and intermediate gray and lateral white regions, permeability to Evans blue-albumin was still elevated but clearly less than at 30 minutes. The permeability to Evans blue-albumin remained elevated in ventral white regions of the spinal cord (Figure 3). At 8 hours of reperfusion, when seven of nine rabbits could still hop, the Evans blue-albumin in ventral gray matter was not statistically different from baseline, and Evans blue-albumin in dorsal gray matter was significantly lower than at 30 minutes.

During the 8- to 24-hour reperfusion period, permeability to Evans blue-albumin in all gray matter regions progressively increased (Figure 2) while motor function progressively decreased. By 24 hours of reperfusion, only three of 10 rabbits could hop, and the measurement of Evans blue-albumin permeability was at the highest level in all gray regions, and the white matter elevations of Evans blue-albumin were sustained (Figure 3).

Control spinal cord blood flow values in the rabbit were within the range reported by others using the [^{14}C]IAP tracer method,¹⁸ H_2 clearance,¹⁹ or microspheres.²⁰ After 30 minutes of reperfusion following 25 minutes of spinal cord ischemia, spinal cord blood flow in all regions was not different from control levels. At 4 hours, spinal cord blood flow was reduced in the ventral and intermediate gray matter regions (40 ± 5 and 40 ± 4 ml/100 g/min, respectively; $n = 6$, $p < 0.05$) compared with the respective controls (59 ± 5 and 56 ± 5 ml/100

g/min) (Figure 4). At 12 hours after reperfusion, spinal cord blood flow was elevated in the ventral and intermediate gray matter regions (146 ± 30 and 95 ± 23 ml/100 g/min, respectively; $n = 3$, $p < 0.05$) (Figure 4). Spinal cord blood flow in the ventral white and intermediate white matter was also elevated (53 ± 5 and 33 ± 5 ml/100 g/min, respectively; $n = 3$, $p < 0.05$) (Figure 5) compared with controls (22 ± 3 and 23 ± 3 ml/100 g/min; $n = 7$). Hyperemia was still present 24 hours after reperfusion in ventral and intermediate gray (97 ± 19 and 95 ± 17 ml/100 g/min, respectively; $n = 5$, $p < 0.05$) (Figure 4) and ventral and intermediate white matter regions (35 ± 3 and 37 ± 5 ml/100 g/min, respectively; $n = 5$, $p < 0.05$) (Figure 5). Blood flow in the lumbar ventral gray region for all animals in the study was increased in nonhopping (87 ± 15 , $n = 13$) compared with hopping rabbits (52 ± 5 , $n = 12$, $p < 0.05$). No significant changes in spinal cord blood flow were detected in cervical and thoracic spinal cord regions (Figures 4 and 5).

Discussion

Deteriorating stroke described in humans may affect 33% of all stroke victims.¹ In humans, the classification of "deteriorating stroke" is given to patients with an ischemic or hemorrhagic insult to the brain who, after the ictus, exhibit continued loss of neurological function. Deterioration of neurological function after stroke can occur over a 3-week period, with the greatest incidence occurring within 48 hours.² In the rabbit spinal cord ischemia model, a similar observation was reported during reperfusion in which motor function deteriorated throughout the first day after injury following an initial recovery period.³ This observation was the basis for using this model to study the underlying mechanisms of motor deterioration after ischemia. The present model of deteriorating stroke has a distinct advantage in that an integrated CNS function rather than a biochemical or electrophysiological correlate is monitored during the entire postischemic period. Also, anesthetic agents, which can affect the pathophysiology of CNS ischemia, are not used during ischemia or the subsequent functional assessment in this model.

One potential pathophysiological mechanism underlying deteriorating stroke, edema, has been frequently associated with neurological deterioration in humans.^{1,2} Edema in both gray and white matter correlated well with hindlimb motor function in the rabbit spinal cord ischemia model.³ Edema was also significantly elevated in the more severely injured nonhopping compared with hopping animals. Although edema is a common consequence of ischemic injury, the mechanisms by which it develops during reperfusion are not clear. Two mechanisms of edema that are widely accepted include cytogenic edema, which involves cell volume regulating mechanisms, and vasogenic edema, which implies breakdown of the BBB.⁹

Reperfusion with oxygenated blood after ischemia increases BBB damage, whereas permanent ischemia does not.²¹ A unique feature of this phenomenon is demonstrated in our model by a biphasic opening of the blood-spinal cord barrier: the first opening was acute (30 minutes) after reperfusion and followed by a substantial recovery by 4 hours; the second opening, however, was a slow, progressive increase 8-24 hours after

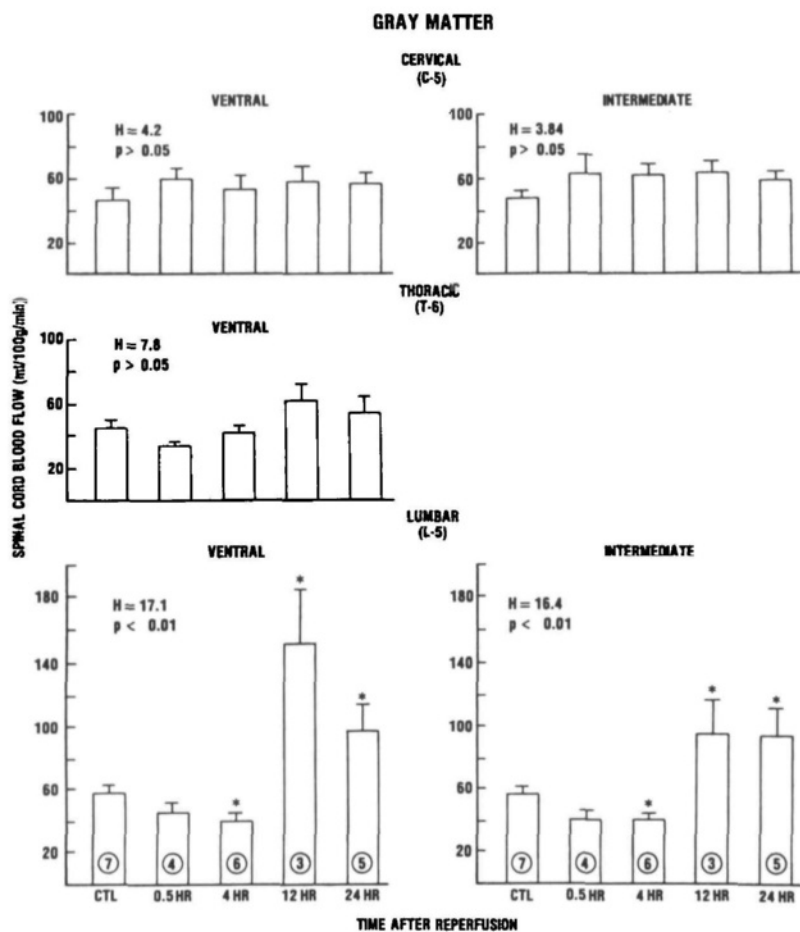


FIGURE 4. Spinal cord blood flow in gray matter after 25-minute ischemia followed by reperfusion. Number in each bar is number of animals per group. *p < 0.05 by Kruskal-Wallis analysis of variance followed by Mann-Whitney U test.

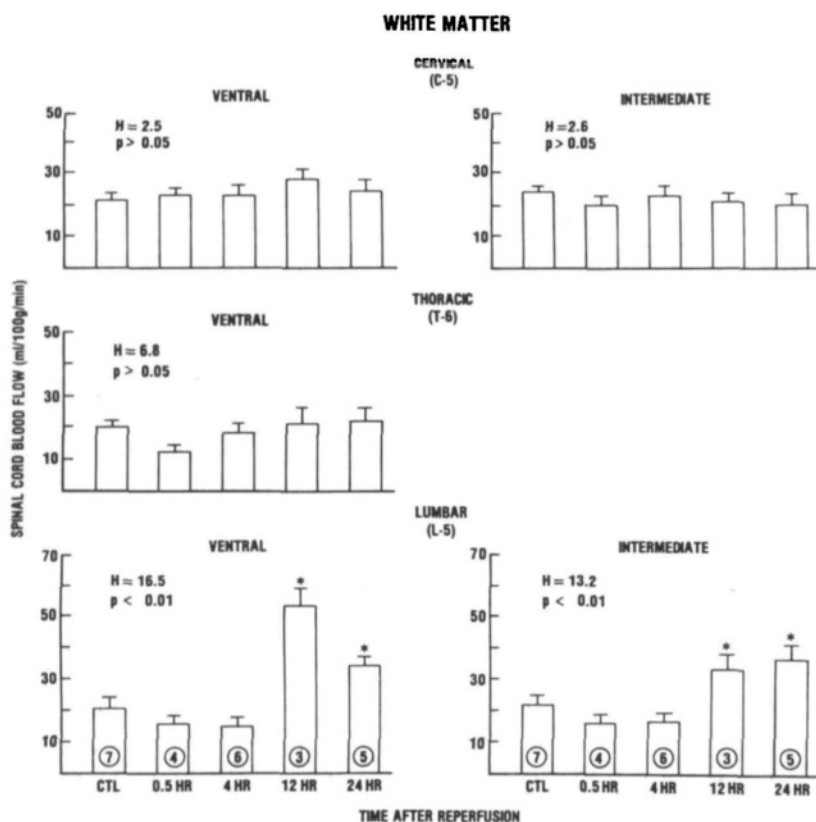


FIGURE 5. Spinal cord blood flow in white matter after 25-minute ischemia followed by reperfusion. Number in each bar is number of animals per group. *p < 0.05 by Kruskal-Wallis analysis of variance followed by Mann-Whitney U test.

reperfusion. This finding was similar to observations made in cats in which the BBB was damaged 15 minutes after reperfusion of the ischemic brain.⁶ The pattern of protein extravasation in gray matter and motor function deterioration progressed in a parallel fashion during the 8- to 24-hour reperfusion period. The major deterioration in motor function occurred during the 8- to 24-hour period, when permeability of the blood-spinal cord barrier to proteins was maximum. However, at 48 hours, blood-spinal cord barrier permeability was minimal, whereas motor function reached its nadir.

The permeability to Evans blue-albumin in white matter regions increased at 30 minutes and remained elevated during the entire reperfusion period. The actual Evans blue-albumin levels, however, were much lower compared with that in gray matter, and the levels did not reflect the changes in motor function. In earlier studies using this model, only minimal histological changes in white matter were observed.^{3,22} In a freezing brain injury model it was demonstrated that edema was present in gray as well as white matter; however, further studies with low molecular weight tracers (e.g., sucrose) indicated that the barrier was intact in white matter, and the exudate spread from the lesioned area in gray matter.²³ This possibility is probably not valid in our model since the Evans blue-albumin in the white matter did not reflect the changes in blood spinal cord barrier permeability in gray matter. This finding suggests that the mechanisms responsible for the changes in barrier permeability in gray matter are probably different from those observed in white matter.

Lumbar spinal cord blood flow was moderately decreased 4 hours after reperfusion while hindlimb motor function was recovering. An opposite relation was seen at later (12–24-hour) time points at which lumbar spinal cord blood flow increased while hindlimb function was deteriorating. The calculated vascular resistance was decreased at 12 hours, suggesting that vasodilation contributed to the increased spinal cord blood flow. The blood flow changes that were observed within 4 hours of reperfusion were consistent with findings in a unilateral carotid occlusion model in gerbils.²⁴ It should be noted that microinhomogeneities in perfusion, which would not have been detected by this method, could exist during the period of functional deterioration.

Hyperemia in the acute stages of stroke is well established, but its clinical significance is unknown.²⁵ The consequences of hyperemia after ischemia can be either beneficial or harmful for recovery, depending on whether the hyperemia is within the ischemic or the peri-ischemic zones. Hyperemia in tissue adjacent to ischemic areas is commonly observed in experimental models of acute focal cerebral ischemia.²⁶ Histological changes were minor in these areas, indicating that the tissue is only marginally impaired.²⁶ The hyperemia we observed after reperfusion is unique in that it developed later and lasted longer compared with that observed in other models.

Hyperemia present in areas of damaged endothelium might exacerbate the development of vasogenic edema and the introduction of blood cells and plasma factors into the tissue, possibly causing further damage to neurons and glia. Secondary neurological deterioration has been attributed to acute cerebral edema after stroke² or mild head injury.^{27,28} Recently, it has been

suggested that the delayed brain swelling and secondary deterioration after mild head injury may be the result of acute cerebral hyperemia.²⁹

In summary, we observed in this highly reproducible model of spinal cord ischemia that secondary deterioration of motor function was correlated with a progressive increase in blood-spinal cord barrier damage, which may in part be amplified by delayed progressive hyperemia. This later, novel phenomenon suggests a possible mechanism in which increased blood-spinal cord barrier permeability enhanced by hyperemia may play a role in the pathogenesis of deteriorating stroke. In addition to indicating a therapeutic opportunity for interventions in this late phenomenon, our study results also call attention to crucial late events in the microcirculation in addition to those emphasized for neuronal cytotoxicity.

Acknowledgments

We wish to thank Ms. Debbie Anderson and Ms. Sharon Nagle for their skillful technical assistance.

References

- Hachinski VC, Norris JW: The deteriorating stroke, in Meyer JS (ed): *Cerebral Vascular Disease 3*. Amsterdam, Excerpta Medica, 1980
- Price TR: Progressing ischemic stroke, in Barnett HJM, Stein BM, Mohr JP, Yatsu FM (eds): *Stroke: Pathophysiology, Diagnosis and Management*. New York, Churchill Livingstone, Inc, 1986, pp 1059–1068
- Jacobs TP, Shohami E, Baze W, Burgard E, Gunderson C, Hallenbeck JM, Feuerstein G: Deteriorating stroke model: Histopathology, edema, and eicosanoid changes following spinal cord ischemia in rabbits. *Stroke* 1987;18:741–750
- Ito U, Spatz M, Walker JT, Klatzo I: Experimental cerebral ischemia in Mongolian gerbils: I. Light microscopic observations. *Acta Neuropathol (Berl)* 1975;32:209–223
- Fujimoto T, Walker JT, Spatz M, Klatzo I: Pathophysiologic aspects of ischemic edema, in Pappius HM, Feindel W (eds): *Dynamics of Brain Edema*. Berlin/Heidelberg/New York, Springer, 1971, pp 171–192
- Kuroiwa T, Ting P, Martinex H, Klatzo I: The biphasic opening of the blood-brain barrier to proteins following temporary middle cerebral artery occlusion. *Acta Neuropathol* 1985;68:122–129
- Petito CK: Early and late mechanisms of increased vascular permeability following experimental cerebral infarction. *J Neuropathol Exp Neurol* 1979;38:222–234
- Ito U, Go KG, Walker JT, Spatz M, Klatzo I: Experimental cerebral ischemia in Mongolian gerbils: III. Behaviour of the blood-brain barrier. *Acta Neuropathol (Berl)* 1976;34:1–6
- Klatzo I: Pathophysiological aspects of brain edema. *Acta Neuropathol (Berl)* 1987;72:236–239
- Suzuki R, Yamaguchi T, Kirino T, Orzi F, Klatzo I: The effects of 5-minute ischemia in mongolian gerbils: I. Blood-brain barrier, cerebral blood flow, and local cerebral glucose utilization changes. *Acta Neuropathol (Berl)* 60:207–216
- Zivin JA, Degirolami U: Spinal cord infarction: A highly reproducible stroke model. *Stroke* 1984;11:200–202
- Hallenbeck JM, Leitch DR, Dutka AJ, Greenbaum LJ: The amount of circumscribed brain edema and the degree of post-ischemic neuronal recovery do not correlate well. *Stroke* 1982;13:797–804
- Saria A, Lundberg JM: Evans blue fluorescence: Quantitative and morphological evaluation of vascular permeability in animal tissues. *J Neurosci Methods* 1983;8:41–49
- Kochanek PM, Dutka AJ, Kumarok KK, Hallenbeck JM: Effects of prostacyclin, indomethacin, and heparin on cerebral blood flow and platelet adhesion after multifocal ischemia of canine brain. *Stroke* 1988;19:693–699
- Siegel S: *Nonparametric Statistics for the Behavioral Sciences*. New York, McGraw-Hill Book Co, 1956
- Elliot KAC, Jasper H: Measurement of experimentally induced brain swelling and shrinkage. *Am J Physiol* 1949;157:122–129
- Rapoport SI: *Blood-Brain Barrier in Physiology and Medicine*. New York, Raven Press, Publishers, 1976

18. Zivin JA, Waud DR: A precise and sensitive method for measurement of spinal cord blood flow. *Brain Res* 1983;258:197-200
19. Tamura A: Measurement of spinal cord blood flow in rabbits: Central gray matter flow and CO₂ reactivity. *No To Shinkei* 1978;30:383-386
20. Nystrom B, Stjernschantz J, Smedegard G: Regional spinal cord blood flow in the rabbit, cat and monkey. *Acta Neurol Scand* 1984;70:307-313
21. Todd NV, Picozzi P, Crockard HA, Ross Russell RW: Duration of ischemia influences the development and resolution of ischemic brain edema. *Stroke* 1986;17:466-471
22. Degirolami U, Zivin JA: Neuropathology of experimental spinal cord ischemia in the rabbit. *J Neuropathol Exp Neurol* 1982;41:129-149
23. Blasberg RG, Gazendam J, Patlak CS, Fenstermacher JD: Quantitative autoradiographic studies of brain edema and a comparison of multi-isotope autoradiographic techniques, in Cervos-Navarro J, Ferszt R (eds): *Brain Edema: Pathology, Diagnosis and Therapy*. New York, Raven Press, Publishers, 1979;28:255
24. Levy DE, Van Uiter RL, Pike CL: Delayed post-ischemic hyperperfusion: A potentially damaging consequence of stroke. *Neurology* 1979;29:1245-1252
25. Olsen TS, Larsen B, Skriver EB, Herning M, Enevoldsen E, Lassen NA: Focal cerebral hyperemia in acute stroke: Incidence, pathophysiology and clinical significance. *Stroke* 1981;12:598-607
26. Yamaguchi T, Waltz AG, Okazaki H: Hyperemia and ischemia in experimental cerebral infarctions: Correlation of histopathology and regional cerebral blood flow. *Neurology* 1971;21:565-578
27. Pickles W: Acute focal edema of the brain in children with head injuries. *New Engl J Med* 1949;240:92-95
28. Snoek JW, Minderhoud JM, Wilmink JT: Delayed deterioration following mild head injury in children. *Brain* 1984;107:15-36
29. Bruce DA, Alavi A, Bilaniuk LT, Dolinskas C, Obrist W, Uzzell B: Diffuse cerebral swelling following head injury in children: The syndrome of malignant brain edema. *J Neurosurg* 1981;54:170-178